

**Case 1 (January 09 2014):** [N Engl J Med. 370\(2\):159-166](#)

**Demographic:** Male, 32 years, North America

***Clinical features extracted from the case and entered into the query box:***

loss of vision  
conjunctival injection  
eye dryness  
eye discharge in mornings  
corneal melting  
right hip pain with radiation to knee  
acneiform rash on face and lower legs  
alcohol and drug use  
petechiae on soft palate  
follicular horny papules  
perifollicular erythema  
flat affect  
afferent pupillary defect  
bilateral corneal opacity

***Synonyms used by Isabel for the above query:***

loss of vision  
conjunctival injection  
eye dryness  
flat affect  
afferent pupillary defect

**STOP !**

**Before you read further you might want to construct your own:**

- Complete differential diagnosis
- Final diagnosis

**In the following section you will find:**

- The differential diagnosis constructed by the MGH panel
- The final diagnosis of the case
- Which of the MGH panel differential diagnoses did Isabel contain
- Did Isabel suggest the final diagnosis

***Differential Diagnoses considered by the MGH panel:***

Keratitis

**Final Diagnosis of the case according to NEJM:**

Severe vitamin A, C and D deficiencies

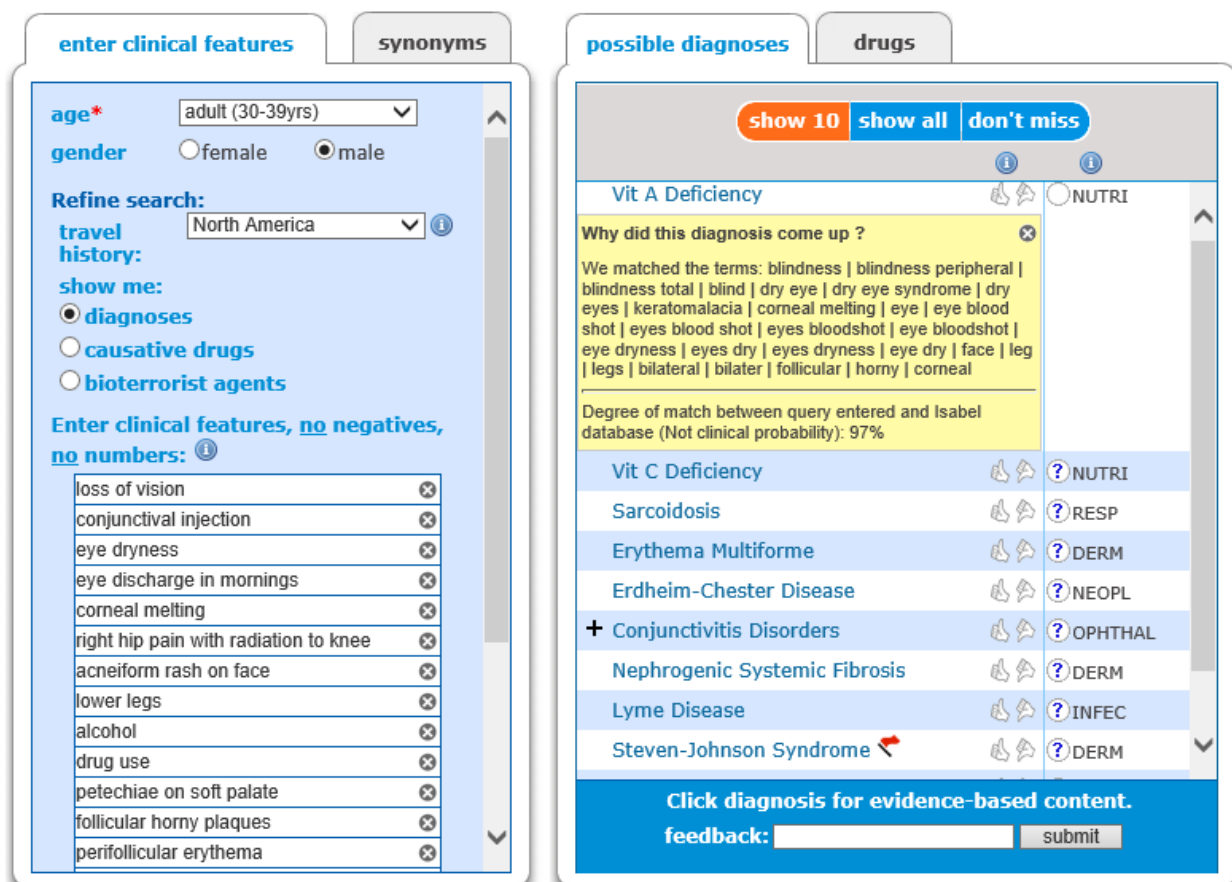
**Differential Diagnoses of the case as given by Isabel:**

Keratitis – Under Ophthalmology

**Was the final diagnosis given by Isabel:**

Yes, Vitamin A and Vitamin C deficiency under Nutrition

**Isabel Checklist Differential:**



The screenshot displays the Isabel Checklist Differential interface, divided into two main panels: 'enter clinical features' and 'possible diagnoses'.

**enter clinical features panel:**

- age\*:** adult (30-39yrs)
- gender:**  female  male
- Refine search:** travel history: North America
- show me:**
  - diagnoses
  - causative drugs
  - bioterrorist agents
- Enter clinical features, no negatives, no numbers:**
  - loss of vision
  - conjunctival injection
  - eye dryness
  - eye discharge in mornings
  - corneal melting
  - right hip pain with radiation to knee
  - acneiform rash on face
  - lower legs
  - alcohol
  - drug use
  - petechiae on soft palate
  - follicular horny plaques
  - perifollicular erythema

**possible diagnoses panel:**

- Buttons: show 10, show all, don't miss
- Vit A Deficiency** (NUTRI)
  - Why did this diagnosis come up? We matched the terms: blindness | blindness peripheral | blindness total | blind | dry eye | dry eye syndrome | dry eyes | keratomalacia | corneal melting | eye | eye blood shot | eyes blood shot | eyes bloodshot | eye bloodshot | eye dryness | eyes dry | eyes dryness | eye dry | face | leg | legs | bilateral | bilater | follicular | horny | corneal
  - Degree of match between query entered and Isabel database (Not clinical probability): 97%
- Vit C Deficiency** (NUTRI)
- Sarcoidosis** (RESP)
- Erythema Multiforme** (DERM)
- Erdheim-Chester Disease** (NEOPL)
- + Conjunctivitis Disorders** (OPHTHAL)
- Nephrogenic Systemic Fibrosis** (DERM)
- Lyme Disease** (INFEC)
- Steven-Johnson Syndrome** (DERM)

Footer: Click diagnosis for evidence-based content. feedback: [input] submit